

**Journal**

**J. Biol. Chem.**  
**Environ. Sci., 2008,**  
**Vol. 3(2): 323-335**  
**[www.acepsag.org](http://www.acepsag.org)**

## **SOME SUBACUTE LIVER AND KIDNEY HAZARDS BY TECHNICAL METALAXYL IN MALE ALBINO RATS**

**Badr M. Abdelwahab<sup>1</sup>, Maged M. Rizk Alla<sup>2</sup>, Ibtisam M. Ibrahim<sup>3</sup> and Tahany A. Ahmad<sup>2</sup>**

<sup>1</sup> Agric. Biochem. Depart., Agric.Fac. Ain Shams Univ.

<sup>2</sup> Cent. Agri. Pest. Lab., Agri. Res. Cent Dokky, Giza, Egypt

<sup>3</sup> Animal Health Res. Inst. Dokky, Giza, Egypt

### **ABSTRACT**

The present study aimed to evaluate biochemically and histopathologically some subacute toxicity aspects for livers and kidneys of albino rats treated with four different doses (50, 100, 150, 200ppm) from the technical fungicide metalaxyl (95%). The biochemical results in respect to liver function showed significant increase in AST enzyme activity after two weeks of treatment with the dose levels 50,150ppm, significant increase in ALT enzyme activity after the first week with the dose levels 50,100,150ppm. Also ALP enzyme activity was increased significantly by the dose level 50 ppm after one week of treatment. In respect of kidney function the data showed significant increase in urea concentration with the dose level 100ppm after one week of treatment, with the dose level 50ppm after the second week, with the dose levels 50,100ppm after the third week and with the dose levels 150,200ppm after the fourth week. Plasma calcium concentration was increased significantly by all used dose levels after the first week of treatment and by the dose levels 100,150ppm after the second week. Also plasma phosphorus concentration was decreased significantly by the dose levels 50,100ppm after the first week of treatment. Most of these changes were disappeared after the recovery period. The liver histopathological examination at the end of treatment period showed some necrosis and vacuolar degeneration change, congestion of blood vessels, infiltration of mononuclear inflammatory cells, thrombus formation in the blood vessels, newly formed bile ductless, severe hemorrhage and peknosis. Kidney tissues showed congestion in blood

vessels, necrosis in some cells lining renal tubules, slight hemorrhage, swelling in wall of blood vessels and infiltration of mononuclear inflammatory cells around the glomerular.

**Keywords:** Metalaxyl, Subacute toxicity, Liver, Kidney, Biochemical parameters, Histopathology.

## INTRODUCTION

The phenyl amid fungicide metalaxyl [N - (2, 6-dimethyl)-N - (2-methyl acetyl)-DL-alanine, methyl ester] is a systemic fungicide that is widely used in agriculture and on horticulture crops for the control of root and stem diseases by inhibiting mycelial growth and spore formation. Metalaxyl is a chiral compound on account of the presence of a stereogenic center in the carboxy alkyl moiety and consists of a pair of enantiomer, S (+) and R (-). Metalaxyl was initially marketed as a racemic mixture (50:50) of R- and S- enantiomeric forms, although its fungicidal activity is almost entirely due to the R- enantiomeric form. The technical grade metalaxyl consists of a minimum of 97% of the R- enantiomer and 3% of the S- enantiomer. Metalaxyl generally is of low acute toxicity but is an eye irritant. It has been classified as a group E carcinogen, that is, a chemical showing evidence of non carcinogenicity for humans. Although people may be exposed to residues of metalaxyl in many food commodities, the chronic dietary risk from all uses is minimal. In this study we investigate some toxic effects in livers and kidneys of male rats administered four different doses of technical metalaxyl (95%).

## MATERIALS AND METHODS

**Chemical:** Technical grade of metalaxyl (95%) produced by El Helb Co. Egypt, was obtained and used in this study.

**Experimental animals:** Adult male albino rats (Wister strain) weighing  $120 \pm 10$  g. were used in the study. Animals were acclimatized for two weeks prior to study under healthy laboratory conditions in the animal house of the Mammalian Toxicology Department, Central Agricultural Pesticides Laboratory and were fed a normal dry diet and allowed free access of water.

**Subacute experimentation:** 50 animals were randomly divided into 5 groups of equal ten rats each. The groups were treated as follows:

- Group 1: The animals were administrated the dose level of 50ppm technical metalaxyl
- Group 2: The animals were administrated the dose level of 100ppm technical metalaxyl
- Group 3: The animals were administrated the dose level of 150ppm technical metalaxyl
- Group 4: The animals were administrated the dose level of 200ppm technical metalaxyl
- Group 5: The animals were received distilled water only to be used as control.

The rats were treated orally by metallic stomach tube for 28 consecutive days and kept without treatment for 14 days as a recovery period.

**Plasma sampling:** From each group of animals, blood samples were obtained at every week of the treatment period (4samples) and at the end of the recovery period, from the retro-orbital plexus of veins, according to the method of Schermer (1967). The samples were collected in clean dry tubes containing heparin as anticoagulant and centrifuged at 600 g for 15 min. then; plasma was separated and kept in a deep freezer at -20°C. until the biochemical measurements were carried out.

**Biochemical parameters:** Commercial diagnostic kits were obtained from Biodiagnostic Egypt Co. and used for some plasma liver and kidney parameters determination, where, for liver, alanine aminotransferase (ALT) and aspartate aminotransferase (AST) activities were determined by the method of Reitman and Frankel (1957), alkaline phosphatase (ALP) activity according to Hausamen et al. (1967) and gamma glutamyltranspeptidase (GGT) activity by the technique of Szasz (1969). For kidney function bioassay, plasma urea concentration were determined according to the method of Coulambes and Farreau (1963), creatinine concentration by the method of Husdan and Rapaport (1968), calcium concentration according to Robertson and Marshall (1979) and phosphorus concentration by the method of Kilching and Freiburg (1951).

**Histopathological examination:** At the end of treatment period, liver and kidney tissues specimens were taken in 10% formalin solution from treated and control animals during the post-mortem examination and were fixed in 10% formal saline. The fixed tissues were washed in tap water, dehydrated in a series of alcohol, cleared in xylene then, embedded in paraffin. Fine microns paraffin sections were obtained and stained with Hematoxylin and Eosin stain as mentioned by Carleton et al. (1967) for histopathological examination.

**Statistical analysis:** Data were expressed as mean $\pm$ SE and significant differences of values were calculated according to the student t-test (Snedecor and Cochran, 1970).

## RESULTS AND DISCUSSION

The oral LD50 of metalaxyl in rats is 669mg/kg. The NOEL was determined to be 12.5mg/kg/day and ADI is 0.03mg/kg. Studies with rats and goats showed rapid metabolism and excretion via urine and feces. Glucuronic acid conjugates of the metabolites were the main rat excretion products (FDA1986). In the present study some subacute liver and kidney hazards by technical metalaxyl (95%) were investigated in male albino rats.

In table(1) it can be noticed, the metalaxyl effects on some liver function enzymes activities where, plasma AST activity showed significant increases by the dose levels 50, 150ppm after two weeks of treatment. Plasma ALT activity showed significant increases by the dose levels 50, 100, 150ppm after the first week. Also the plasma ALP activity was increased significantly after the first week of treatment by the dose level 50ppm and the plasma GGT activity showed significant decreases by the dose levels 100, 50ppm after two and three weeks of treatment respectively. Several changes in liver function enzymes activities were recorded before by many investigators for example, Harada (1984), who said that liver was the target organ of metalaxyl, as indicated by the changes in blood chemistry and increase in liver weight. He also noticed decreased ALT activity in males and changes in ALP, ALT activities. Finn et al, (1977) showed increase in serum ALP levels in high dose treated males and females rats by metalaxyl, which was also time-related.

Table(I) Metalaxyl effects on some liver function.

period	7 days				14 days				21 days				28 days				42 days(Recovery)			
	0	50	100	150	200	0	50	100	150	200	0	50	100	150	200	0	50	100	150	200
Treatment																				
Parameters	mg	mg	mg	mg	mg	mg	mg	mg	mg	mg	mg	mg	mg	mg	mg	mg	mg	mg	mg	mg
ALP	102.10 ± 1.1	111.6 ± 2.9*	106 ± 3.6	106.2 ± 5.4	103.7 ± 4.9	103.8 ± 5.1	107.17 ± 4.6	99 ± 1.7	108.5 ± 3	107.1 ± 3.7	102.6 ± 5	103.8 ± 4.4	104.9 ± 3.9	97.7 ± 1.1	105.7 ± 3.1	100.5 ± 3.8	102.8 ± 2.2	105 ± 2.5	102.7 ± 0.8	103.6 ± 4.5
γ GT	923.9 ± 233.2	555.5 ± 95.5	707.8 ± 150.9	1093.2 ± 68.7	608.4 ± 208.7	1021.4 ± 110.7	560.8 ± 220.3	368.4 ± 125.2*	770 ± 188.9	937.4 ± 95.3	316.6 ± 151*	931.8 ± 55.6	913.5 ± 190.4	583 ± 231.5	558.4 ± 289.8	636.3 ± 187.3	831.4 ± 32.7	744.5 ± 257.1	2236.1 ± 1833.6	714.8 ± 156.3
GOT (AST)	75.2 ± 4.5	98.37 ± 8.6	118.45 ± 17.8	95.2 ± 20.7	110.17 ± 17.6	62.8 ± 8.5	114.7 ± 14.8**	50.12 ± 6.5	64.4 ± 7.1	85.55 ± 30.7	49.17 ± 9.8	121.5 ± 28.2	82.87 ± 9.3	41.55 ± 9.3	48.23 ± 12.8	112.9 ± 28.1	47.6 ± 12.2	107.7 ± 30.1	94.17 ± 26.7	58.57 ± 20.1
GPT (ALT)	54.1 ± 3.3	101 ± 5.9***	95.17 ± 13*	100 ± 2.6***	65.62 ± 9.7	77.4 ± 7.1	86 ± 10.7	72.35 ± 3.5	81.5 ± 4.5	71.15 ± 4.5	70.2 ± 8.2	81 ± 7.3	44.22 ± 13.1	76.2 ± 7.7	61.77 ± 11	71.4 ± 4.9	72.35 ± 12.3	64.9 ± 3	79.8 ± 4.6	73.05 ± 5.8

Data expressed as mean ± S.E.

\* significant difference at  $p \leq 0.05$ \*\* significant difference at  $p \leq 0.01$ \*\*\* significant difference at  $p \leq 0.001$

Data in table(2) represented the metalaxyl effects on some kidney function parameters where, urea concentration showed significant increases by the dose level 100ppm after the first week of treatment, by the dose level 50ppm after the second week, by the dose levels 50,100 ppm after the third week and by the dose levels 150,200at the end of treatment period . Creatinine concentration showed significant decreases by the highest dose level after the first week of treatment, and by the lowest dose level after the third week. Calcium concentration increased significantly by all the used dose levels after the first week of treatment and by the dose levels 100,150ppm after the second week. Phosphorus concentration decreased significantly by the dose levels 50,100ppm after the first week of treatment. Some investigators recorded similar results as Gerspach(1994) who noticed a tendency to decrease urea concentration among males at the dose 300ppm of both metalaxyl-M and metalaxyl . Also in a study of the nephrotoxicity of a combination fungicide(metalaxyl+mancozep)in Wister rats by Sunder and Rao (1998) which the results showed significant alterations in blood urea and creatinine in the serum and histology of the kidneys . Elevated calcium concentration after the exposure of metalaxyl was noticed by Harada (1984) in dogs treated with the dose level 1000ppm for 6 months.

The histopathological examination showed vacuolar degeneration change of some hepatocytes, other hepatocytes were necrosed, kupffer cells activation and disorganization arrangement of hepatic cord in livers of rats treated with 50ppm (fig.1). In rats treated with 100ppm the livers showed congestion of blood vessels, newly formed bile ductless, fibrous connective tissue proliferation of the portal area as well as infiltration of mononuclear inflammatory cells and necrosis of some hepatocytes (fig.3) .Livers of rats administrated 150ppm showed thrombus formation in the blood vessels associated with swelling of the endothelial cells lining it and newly formed bile ductless (fig.5). The dose level 200ppm caused sever hemorrhage which dispersed hepatocytes as well as peknosis of the nucleus and necrosis of some hepatocytes (fig.7).

Table (2) Metalaxyl effects on some kidney function.

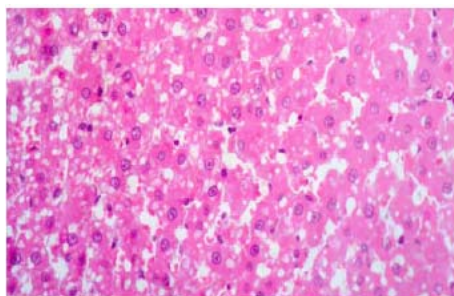
periods	7 days					14 days					21 days					28 days					42 days (Recovery)				
	0	50	100	150	200	0	50	100	150	200	0	50	100	150	200	0	50	100	150	200	0	50	100	150	200
Treatment																									
Parameters																									
Urea mg/dl	15.16 ± 1.22	29.94 ± 5.92	36.5 ± 4.22**	29.31 ± 7.97	16.08 ± 2.58	20.25 ± 2.22	32.25 ± 2.28**	27.19 ± 3.11	32.56 ± 7.61	25.75 ± 1.12	16.69 ± 1.6	26.56 ± 2.45*	28 ± 2.66**	30.37 ± 8.03	22.06 ± 4.52	17.31 ± 1.49	18.69 ± 3.36	23.25 ± 4.39	25.25 ± 1.6*	26.87 ± 1.33**	17.62 ± 1.14	20.75 ± 3.18	9.75 ± 3.74	21.31 ± 2.47	28.31 ± 5.52
Creatinine mg/dl	7.35 ± 0.59	8.11 ± 2.05	6.35 ± 0.89	7.25 ± 1.0	4.91 ± 0.71*	5.93 ± 0.31	4.41 ± 0.6	5.94 ± 1.63	4.95 ± 1.2	7.08 ± 1.1	6.07 ± 0.25	3.02 ± 1.05*	4.82 ± 0.56	7.91 ± 1.1	7.89 ± 1.52	4.96 ± 0.52	4.51 ± 0.46	6.88 ± 1.29	6.59 ± 1.76	7.11 ± 1.6	7.41 ± 0.64	5.37 ± 0.62	5.31 ± 0.44*	6.74 ± 1.21	3.18 ± 1.02*
Calcium mg/dl	9.03 ± 1.15	17.84 ± 0.76***	17.88 ± 1.64**	14.66 ± 0.9**	15.98 ± 1.14**	8.56 ± 2.01	14.16 ± 1.52	14.94 ± 1.43*	14.59 ± 1.27*	12.14 ± 1.31	7.75 ± 1.26	8.99 ± 2.62	8.64 ± 1.42	7.97 ± 0.74	8.24 ± 0.79	8.80 ± 1.05	7.98 ± 0.46	9.06 ± 1.45	7.52 ± 0.22	7.53 ± 1.68	7.38 ± 1.44	8.63 ± 0.83	9.58 ± 1.67	8.0 ± 1.21	9.91 ± 2.95
Phosphorus mg/dl	10.14 ± 2.22	3.66 ± 1.14*	3.14 ± 1.24*	5.45 ± 1.91	3.93 ± 2.06	8.54 ± 3.08	4.71 ± 1.41	5.96 ± 1.58	5.71 ± 2.08	8.01 ± 1.57	7.78 ± 1.97	8.29 ± 1.46	6.35 ± 2.73	9.40 ± 2.93	4.85 ± 3.01	6.92 ± 2.65	7.41 ± 0.3	8.27 ± 2.54	12.3 ± 1.16	5.92 ± 1.42	8.57 ± 2.99	5.64 ± 2.9	11.51 ± 0.95	7.10 ± 2.26	6.90 ± 2.22

Data expressed as mean ± S.E.

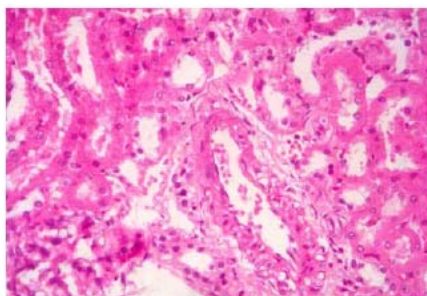
\* significant difference at  $p \leq 0.05$ \*\* significant difference at  $p \leq 0.01$ \*\*\* significant difference at  $p \leq 0.001$

Kidney tissues examination showed congestion in blood vessels and necrosis in some cells lining renal tubules in rats treated with 50ppm (fig.2). While the effect of 100ppm on kidneys produced some renal casts in some tubules and some cells lining renal tubules were necrosed with slight hemorrhage (fig.4). In kidneys from rats treated with 150ppm, we noticed also sever renal cast formation, necrosis in cells lining renal tubules with slight hemorrhage and swelling in walls of blood vessels (fig.6).The effect of the dose level 200ppm on kidney tissues showed hemorrhage, fibrous connective tissue proliferation and infiltration of mononuclear inflammatory cells around the glomeular (fig.8) .Similar investigation had been carried out by Suzzuki et al.(1985), who reported that the pathological examination revealed turbid swelling of the kidney tissue and acute tubular necrosis , they added that the focal necrosis of the liver was observed .Bhasker reddy et al.(1995) studied the histopathological effect of metalaxyl at 500and 2000ppm levels on albino rats, the effects were mild to moderate multifocal necrosis, cellular infiltration and fatty infiltration in livers of rats fed with 2000ppm .Haschek and Rousseaux (1991) studied the effect of metalaxyl at 1000ppm administered to rats, the findings were hepatocytes vaculation accompanied by necrosis and they found sever fatty change of the liver accompying inflammatory changes .

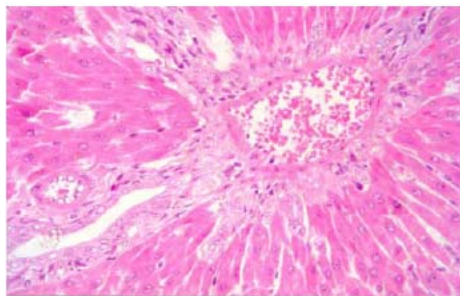




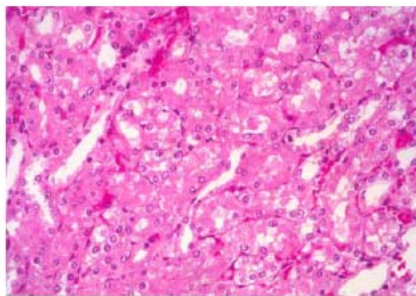
**Fig (1) -Liver of rats administrated 50 mg/ kg metalaxyl showing vacular degenerated change of some hepatocytes other hepatic cells were necrosed , activation of kupffer cells and desorganzation of arrangement of hepatic cord (H and EX 400) .**



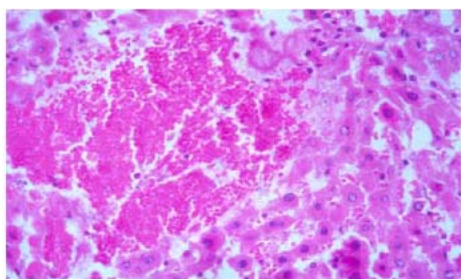
**Fig (2) - Kidney of rats administrated 50 mg / kg metalaxyl showing congestion in blood vessels and necrosis in some cells lining renal tubules (H and EX 400).**



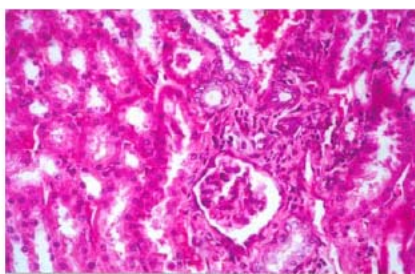
**Fig (3) -Liver of rats administrated 100 mg/kg metalaxyl showing congestion of blood vessels , newly formed bile ductules , fibrous connective tissue proliferation of the portal area as well infiltration of mononuclear inflammatory cells and necrosis of some hepatocytes ( H and Ex 400).**



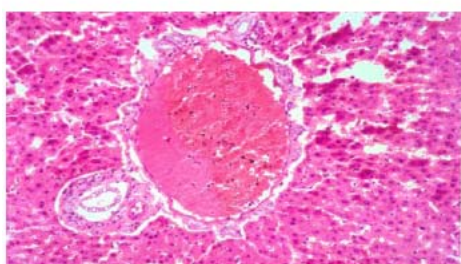
**Fig (4)-Kidney of rats administrated 100 mg /kg metalaxyl showing some renal tubules formed renal cast in their lumen , some cells of lining renal tubules are necrosed with slight hemorrhage (H and EX 400).**



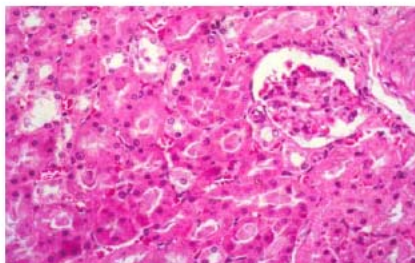
**Fig (5)** Liver of rats administrated 150 mg/kg b.w metalaxyl showing thrombus formation in the blood vessel associated with swelling of the endothelial cells lining it, newly formed bile.



**Fig (6)** -Kidney of rats administrated 150 mg/ kg metalaxyl showing severe renal cast formation, necrosis in cells lining renal tubules, slight hemorrhage as well as swelling in wall of blood vessels (H and EX 400).



**Fig (7)**-Liver of rats administrated 200 mg/kg metalaxyl showing severe hemorrhage, disorganized hepatocytes as well as pyknotic nuclei and necrosis of some hepatocytes (H and EX400).



**Fig (8)**- Kidney of rats administrated 200 mg /kg metalaxyl showing hemorrhage, fibrous connective tissue proliferation and infiltration of mononuclear inflammatory cells around the glomerulus (H and EX 400).

## REFERENCES

- Bhaskor reddy , M. V. , Krishnomurthi, M.K. and Shelly, H.S. (1995). Short term dietary toxicity of Apron 35 SD(metalaxyl)to albino rats *rattus norvegicus albinus*. Pesticide Research Journal Vol.2 (2):139-144.
- Carleton, H.M., Druy, R. A., Willington, E. A. and Caneron, S. (1967). Histological Technique 4<sup>th</sup> Ed. Oxford Univ. Press NY Toronto.
- Coulombes, J.J. and Farreau, A.O. (1963). A new simple semi micro method for colorimetric determination of urea. Clin. Chem. ,9:102-104.
- Finn, J. P., Briggs, K. , Close, J. E. , Noble, D. N., Barrett, R. and Rider, L. (1977). CGA48988, 91-day dietary toxicity study in beagle dogs. Report from Hazleton Laboratories Europe Ltd., Harrogate, He lpy, England, Submitted from Ciba-Geigy Ltd., Basle, Switzerland, to the World Health Organization by Ciba-Geigy Ltd.(unpublished).
- Food and Drug Administration (1986). The FDA Surveillance Index Bureau of Foods, Dept of Commerce, National Technical Information Service, Springfield, VA.
- Gerspach, R. (1994). 28 days subacute, oral toxicity study in rats (gavage). Comparison of toxicity profiles of CGA 329351 tech. and CGA 48988 tech. Unpublished report No. 933180, dated 26 august 1994, from Ciba-Geigy Ltd, Stein, Switzerland . Submitted to WHO by Syngenta Crop Protection AG, Basel, Switzerland.
- Harada, T. (1984). CG117 (CGA48988)-24-month oral chronic toxicity study in dogs. Unpublished report dated 6 October 1984, from Institute of Environment Toxicology, Japan. Submitted to WHO by Syngenta Crop Protection AG, Basel, Switzerland.
- Haschek, W. M. and Rousseaux, C.G. (1991). Handbook of toxicologic pathology, San Deigo, California: Academic Press, pp 279-294.
- Hausamen, T. V., Helger, R., Rick, W. and Gross, W. (1967). Optical conditions for the determination of serum alkaline phosphatase by a new kinetic method. Clin. Chem. Acta, 15: 241-245.
- Husdan, H. and Rapaport, A. (1968). Estimation of creatinine by jaffe reaction, a comparison of methods. Clin. Chem., 14:222-238.

- Kilchling, H. and Freiburg, T. (1951). Inorganic phosphorus in serum and alkaline phosphate in serum . In : Clin. Photometric, 3<sup>rd</sup> Ed., Wiss, Verl. Ges. M6H, Stuttgart .
- Reitman, S. and Frankel, S. (1957). A colorimetric method for the determination of serum glutamic oxaloacetic and glutamic pyretic transaminaes . Am. J. Clin. Path. , 28 : 56 – 63 .
- Robertson, W. G. and Marshall, R. W. (1979). Calcium measurement in serum and plasma total and ionized. Crc. Crit. Ren. Clin. Lab. Sci. , 13 : 271-304 .
- Schermer, S. (1967). The blood morphology of laboratory animals 3<sup>rd</sup> Ed. Davis FA Co., Philadelphia, P; 42.
- Snedecor, G. W. and Cochran, W. G. (1970). Statistical methods 14<sup>th</sup> Ed. Iowa State Univ. Press, pp. 593-598.
- Sundar, S. R. and Rao, M. V. (1998). Nephrotoxicity of a combination fungicide (metalaxyl+mancozeb) in wistar rats-a clinicopathological assessment. Indian J. Envi. Toxi. , 8(2) : 69-71 .
- .Suzuki, K., Kaboyashi, M., Ito, A. and Nakgawa, M. (1985). Poisoning of grazing cattle: observations on spontaneous and experimental cases. Cornell Veterinarian, 75(2) 348-365.
- Szasz, G. (1969). A kinetic photometric method for serum gamma glutamyl transpeptidase . Clin. Chem. , 15 : 124 -136 .

## بعض الأضرار تحت الحادة للكبد والكلى بواسطة الميتالأكسيل الخام في ذكور الفئران البيضاء

بدر محمد عبد الوهاب<sup>1</sup>، ماجد منصور رزق الله<sup>2</sup>، أبتسام محمد إبراهيم<sup>3</sup>، تهاني عبد الغفار أحمد<sup>2</sup>

<sup>1</sup> قسم الكيمياء الحيوية-كلية الزراعة-جامعة عين شمس، <sup>2</sup> قسم سمية المبيدات للتدبيات والأحياء المائية-المعمل المركزي للمبيدات-مركز البحوث الزراعية، <sup>3</sup> معهد بحوث صحة الحيوان-مركز البحوث الزراعية .

أجريت هذه الدراسة لتقييم بعض جوانب السمية تحت الحادة لأكباد وكلى الفئران البيضاء المعاملة بأربع تركيزات مختلفة (200,150,100,50 جزء في المليون) من المبيد الفطري الميتالأكسيل الخام (95%) بيوكيماويا وهيستوباثولوجيا. وقد أظهرت النتائج البيوكيماوية فيما يخص وظائف الكبد حدوث زيادة معنوية في نشاط إنزيم AST بعد أسبوعين من المعاملة بالتركيزين 150,50 جزء في المليون وكذلك حدوث زيادة معنوية في نشاط إنزيم ALT بعد الأسبوع الأول بالتركيزات 150,100,50

. أيضا زاد معنويا نشاط إنزيم ALP بواسطة التركيز 50 جزء في المليون بعد أسبوع من المعاملة . ومن ناحية وظائف الكلى أظهرت النتائج حدوث زيادة معنوية في تركيز اليوريا في البلازما بواسطة التركيز 100 جزء في المليون بعد الأسبوع الأول من المعاملة وبواسطة التركيز 50 بعد الأسبوع الثاني وبالتركيزين 50 و100 بعد الأسبوع الثالث وبالتركيزين 150 و200 بعد الأسبوع الرابع . أيضا حدثت زيادة معنوية في تركيز الكالسيوم بواسطة كل مستويات الجرعة المستخدمة بعد الأسبوع الأول من المعاملة وكذلك بالتركيزين 100 و150 جزء في المليون بعد الأسبوع الثاني . وحدث كذلك انخفاض معنوي في تركيز الفسفور بواسطة التركيزين 50 و100 جزء في المليون بعد الأسبوع الأول من المعاملة وقد اختلفت معظم هذه التغيرات المعنوية بعد فترة توقف المعاملة . أما الفحص الهيستولوجي لأنسجة الكبد في نهاية فترة المعاملة فقد اظهر حدوث بعض التناثر والتضخم في خلايا الكبد ووجود فقاعات في سيتوبلازم الخلايا المتضخمة وحدث احتقان للأوعية الدموية وانتشاحات للخلايا الالتهابية في المنطقة المركزية لكل من فصي الكبد وحدث جلطة في الأوعية الدموية مع انتفاخ لخلاياها وزيادة في عدد خلايا الحويصلة المرارية وكذلك حدوث أنزفة حادة وتخسر في النواة . وبفحص أنسجة الكلى ظهر حدوث احتقان للأوعية الدموية وتناثر بعض الخلايا في الأنابيب الكلوية وأنزفة بسيطة وانتفاخ في جدر الأوعية الدموية وانتشاح في الخلايا الالتهابية حول الحويصلة .